SONOGRAPHIC ASSESSMENT OF POSTVOID RESIDUAL URINE VOLUMES IN PATIENTS WITH BENIGN PROSTATIC HYPERPLASIA

Adewumi O. Amole, FWACS; Sulyman A. Kuranga, FWACS; and Benjamin A. Oyejola, PhD
Ilorin, Kwara State, Nigeria

Objective: To derive a formula that defines the postvoid residual (PVR) urine volume more accurately in patients with prostatic gland enlargement.

Design: Prospective.

Setting: Department of Radiology, University of Ilorin Teaching Hospital, Ilorin.

Subject: Fifty-two consecutive patients with benign prostatic hyperplasia. The mean age was 64.98±9.57 years.

Method: PVR urine was evaluated by ultrasonography. Each patient had two examinations, the first of which was with a full bladder and the second of which was immediately after voiding. Two orthogonal diameters were measured on each bladder section (longitudinal and transverse) in the supine position. Fifty-two paired sets of ultrasonic measurements were thus obtained. Catheterized postvoid urine residue was regarded as the gold standard.

Results: Using these measurements, an equation—[PVR_{CUBIC}=374.057+(-196.94+V1)+(32.5539+$V1^2$)+(-1.1480+$V1^3$) where V1=average of the length (L), width (T), and the anteroposterior distance on transverse section (Dt) of the postvoid urinary bladder]—more accurate than previously existing ones was obtained by cubic regression analysis. Mean ultrasound estimated volume was 220.51 ml as against 220.76 ml after catheterization. The mean difference was 0.25 ml (not significant, $p<0.01$) with 95% confidence interval of ±10 ml. With this equation, the ultrasonographic residual urine volume showed a higher correlation coefficient with the catheterized volume at $p<0.01$ (Pearson r=0.982, r^2=0.96) than previously defined formulas. The standard error of the mean was 5.11 ml (mean=220.5±190.4 ml).

Conclusion: With the above equation, we consider conventional transabdominal ultrasonography a reliable method for assessing the residual urine volume in patients with benign prostatic hyperplasia. This equation, though complex when compared to some of the pre-existing formulas, can be integrated into the memory of modern ultrasound machines for easy and faster computation. (*J Natl Med Assoc.* 2004;96:234–239).

Key words: prostate gland ♦ ultrasonography ♦ urine residue

© 2004. From the Department of Radiology (Amole) and Department of Surgery, University of Ilorin Teaching Hospital, Ilorin, Nigeria (Kuranga); and Department of Statistics, Faculty of Science, University of Ilorin, Ilorin, Nigeria (Oyejola). Send correspondence and reprint requests for *J Natl Med Assoc.* 2004;96: 234–239 to: Dr. A.O. Amole, Department of Radiology, Faculty of Health Sciences, University of Ilorin, Ilorin, Kwara State, Nigeria; e-mail: wamole@skannet.com

INTRODUCTION

Significant postvoid residual (PVR) urine volume is a frequent manifestation of benign prostatic hyperplasia. Assessment of this volume forms an important routine investigation, as serial measurements may indicate clinical progress[1-4]. Bladder catheterization is, however, widely regarded as the gold standard of measurement[1,4-8]. Nevertheless, it carries the risk of infection and trauma to the urethra.[1,5,7,8] In addition, it has been reported to be inaccurate to some extent.[8,9] Ultrasonography, as a nonin-

vasive method of rapidly assessing residual urine volume has thus been recommended as an alternative to catheter estimations by many authors.[4,9-14] However, while some workers[5,15] advocate caution when interpreting PVR measurements by transabdominal ultrasound, others consider it inaccurate.[6,7] Against this background, we present our experience in PVR measurements of urine in patients with benign prostatic hyperplasia.

MATERIALS AND METHODS

Fifty-four consecutive patients with symptoms and clinical signs of prostatic gland enlargement had transabdominal ultrasonography at the Department of Radiology, University of Ilorin Teaching Hospital, Ilorin, between January and August 2001. Of these, two were excluded from the study, as bladder catheterization was impossible due to concomitant urethral stricture. Patients with in-dwelling bladder catheters due to acute urinary retention or neurological disorders were not included in the study. Also excluded were patients with sonographic evidence of dilatation of the upper renal tract and vesical diverticula. Mean age was 64.98±9.57 years (range 47–100 years).

Each patient had two examinations, the first of which was with a full bladder and the second of

Figure 1. Pelvic Sonograph Showing Measuring Calipers in Longitudinal and Transverse Images of the Urinary Bladder

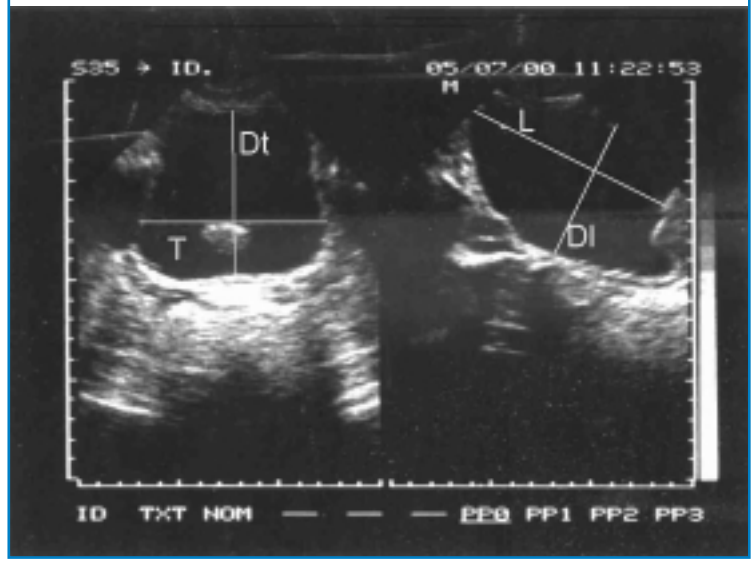

Figure 2. Scatter Plots of CV Against Dl, L, T and Dt.

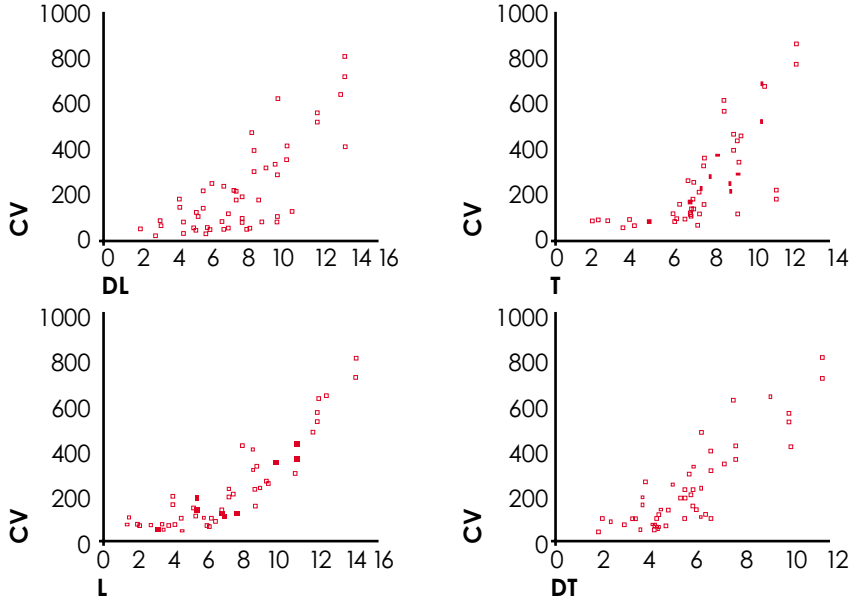

which was immediately after voiding. With the subject lying supine, the transducer was positioned to view the maximum longitudinal section, usually at the midline. Maintaining the same contact point the transducer was rotated through 90 degrees and then angled up and down to find the largest transverse area. Two orthogonal diameters were then measured on each of these bladder sections. On the maximal longitudinal image, the maximum longitudinal (L) and anteroposterior diameters (Dl) were taken. On the maximal transverse image, the maximum transverse diameter (T) and height (Dt) were obtained (Figure 1). These measurements were recorded for both examinations. To minimize observer error at the stage of imaging, one sonologist acquired and measured all images using specific guidelines. To exclude prejudice, an assistant who had no knowledge of the ultrasound measurements catheterized each patient to assess the PVR volume under strict asepsis. This volume was regarded as the gold standard. Complete drainage of the bladder was ensured by suprapubic expression of the urinary bladder under ultrasonic guidance and cessation of urine flow from the catheter. Catheterized residual urine volume ranged between 26 and 801 ml (mean 220.76±194.40 ml), while the ultrasonographic estimates were between 33.2 and 772 ml (mean 220.51±190.46 ml).

All examinations were carried out with a Siemens Sonoline Sx scanner with a 3.5-MHz transducer. A measuring cylinder was used to determine the catheterized volume.

Figure 3. Scatter Plots of CV Against V1, V2 and V3

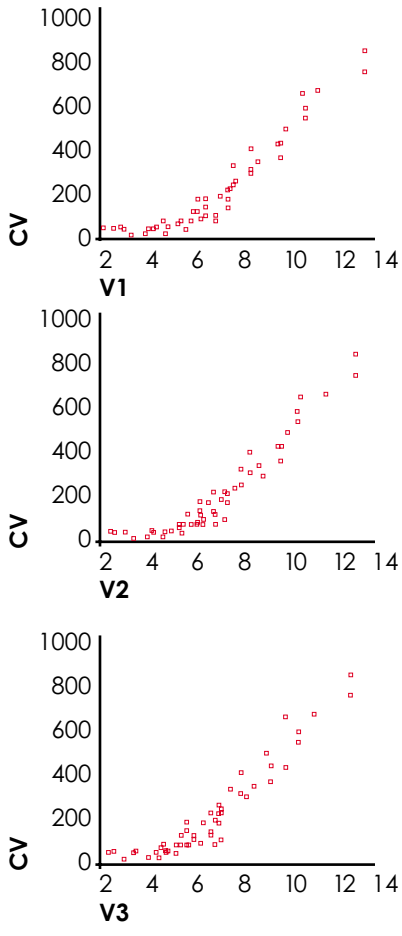

ANALYSIS AND RESULTS

The variables L, T, Dt, and Dl were considered in estimating the actual bladder volume. The relationship between the volume and these variables was examined. The scatter plots of volume against each of the variables revealed curvilinear relationships (Figure 2).

Since the relationship is described by a curve, the Spearman correlation coefficient was therefore used as the appropriate test to determine the degree of correlation between the actual residual urine volume and these variables. Dl was found to have the least correlation.

Inasmuch as a change in urine volume will alter at least one of these variables, we decided to find an average of these parameters, that is, (T+L+Dt)/3 which we referred to as V1, (T+L+Dl)/3 referred to as V2 and (T+L+Dt+Dl)/4 which we referred to as V3. The scatter plots of V1, V2 and V3 against CV are given in Figure 3. The plots indicate a curvature. By Spearman's rank correlation, V1 was found to correlate best with the actual residual volume (CV).

Linear, quadratic, and cubic models of V1 were then fitted to the actual residual volume CV. The r^2 values show that the quadratic and cubic models perform better than the linear model. Using the cubic model of V1 the sonographic estimate of PVR can be obtained as PVR_{CUBIC}=374.057+(-196.94+V1)+(32.5539+$V1^2$)+(-1.1480+$V1^3$).

When the estimates of volume from this model (PVR_{CUBIC}) were compared using paired samples t-test with the estimates by methods proposed by Brunn and Ruf[11], McLean and Edell[16], Orgaz and associates[17], and Simpson[5], we obtained the results in Table 1. Mean deviation from actual catheter volume was

lowest for PVR_{CUBIC}. It also had the lowest standard deviation. The confidence limits are also smallest for the model. There was underestimation by the Orgaz method and overestimation by McLean's method.

Scatter plots of actual residual volume against these sonographic estimates are shown in Figure 4, and the results of linear regression analysis of the actual volume on the estimates from various methods are given in Table 2. The results show that estimates from PVR_{CUBIC} performed better than the other methods. The constant for the model is not significantly different from 0, and the regression coefficient β is not significantly different from 1. The constant is the closest to zero and the regression coefficient is closest to 1. This implies that the PVR_{CUBIC} model gives the best estimate to volume.

DISCUSSION

Significant postvoid residuals can result in symptoms of urinary frequency, nocturia, overflow incontinence, and recurrent urinary tract infections. Measurement of this residual volume is important to rule out both neurologic abnormalities and/or obstructive voiding disorders. In managing patients with prostatic gland enlargement, it is very useful in the initial assessment and monitoring of clinical progress. With an increase in the scope of pharmacological treatment options in cases of such urinary problems, there is a growing need for a rapid and noninvasive as well as accurate evaluation. Over the years, residual urine has been measured by catheterization of the urethra, which is generally accepted as accurate. It, however, carries the risk of infection and trauma to the urethra. In the past three decades, ultrasonography has been an alternative method of evaluating the urinary bladder volume. Its accuracy has, however, remained contentious. Although several studies[1-20] have been done using different types of scanners, clinical conditions, and subjects, controversies still exist over the accuracy of this method when compared with the traditional bladder catheterization[21-30]. Orgaz et al.[17] attributed the inaccuracy of some of the previous reports to the assumption that the urinary bladder has a fixed geometric shape. For instance, the bladder was assumed ellipsoid by Simpson[5]. This assumption can only be true within a particular range of bladder volume, as the shape changes with the volume. Since the urinary bladder is not a rigid, hollow viscus and is surrounded by other pelvic structures that may limit its expansion in certain directions, we considered that an increase in size would lead to an increase in at least one out of

Figure 4. Showing the Relationship Between True Residual Urine Volume and Various Sonographic Estimates

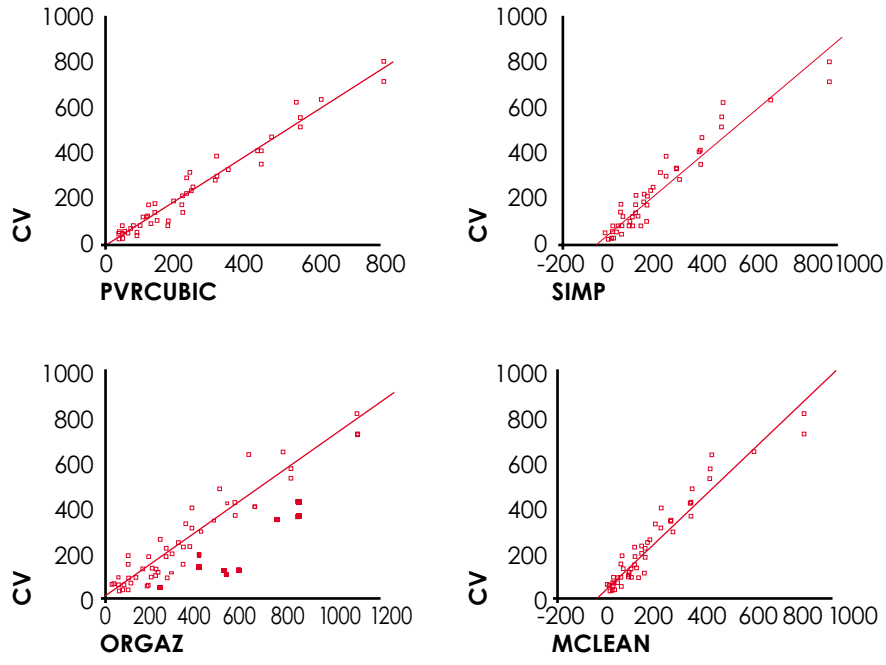

Table 1. Results of Paired Samples T-Test Between PVR_{CUBIC} and Some Other Formulas

	Paired Differences							
				95% Confidence Interval of the Difference				
	Mean	Standard Deviation	Standard Error Mean	Lower	Upper	t	df	Sig. (2-tailed)
CV—PVR_{CUBIC}	0.2462	36.8691	5.1128	-10.0183	10.5106	0.048	51	0.962
CV—SIMPSON	13.5346	59.3724	8.2335	-2.9948	30.0640	1.644	51	0.106
CV—ORGAZ	-70.2746	86.3233	11.9709	-94.3072	-46.2421	-5.870	51	0.000
CV—MCLEAN	39.8473	52.7301	7.3124	25.1672	54.5275	5.449	51	0.000
CV—BRUNN	-8.8282	89.2783	12.3807	-33.6834	16.0270	-0.713	51	0.479

Table 2. Results of Linear Regression Analysis of the Actual Volume on the Estimates From Various Methods

	Constant	SE	β	SE (β)	r
PVR_{CUBIC}	-0.228	9.821	1.002	0.027	0.98
SIMPSON	39.948	10.313	0.873	0.035	0.96
ORGAZ	3.119	12.973	0.748	0.034	0.95
MCLEAN	41.381	10.274	0.992	0.039	0.96
BRUNN	52.642	11.312	0.732	0.032	0.95

PVR_{CUBIC}=The sonographic urine volume estimate obtained by our new method
SE=Standard error
β=Regression coefficient
r=Correlation coefficient
SE (β)=Standard error of regression coefficient

the three dimensions. We therefore decided to use the average of the three dimensional measurements ({L+T+ Dl}/3). A review of the literature further showed that efforts at deriving a simple empirical formula not based on geometric shape resulted in wider range of errors.[2,21] Our formula—[PVR_{CUBIC} =374.057+(-196.94+V1)+(32.5539+ $V1^2$)+(-1.1480 +$V1^3$) where V1=average of the length (L), width (T), and depth (Dt) of the postvoid urinary bladder]—which does not describe any known measurement or geometrical figure but seems highly accurate in the calculation of bladder volume, was obtained by cubic regression analysis. This yielded the most accurate PVR measurements by a portable general-purpose ultrasound machine to date when compared with previous studies.[2,9,17,19-30] We attribute these results to a dynamic three-dimensional volumetry rather than a fixed geometric formula.

Our equation, though complex, is most accurate over a wider range of bladder volume than any of the pre-existing formulas,[20-30] and can be integrated into the memory of modern ultrasound machines for easy and faster computation. Hence, we consider conventional transabdominal ultrasonography a reliable, safe, and rapid method for assessing the residual urine volume in patients with benign prostatic hyperplasia. With an increase in demand for pharmacological treatment for benign prostatic enlargement, this examination can be repeated as often as necessary as an office-based procedure to monitor progress of treatment without the risk of trauma or infection to the urinary tract.

REFERENCES

1. Milakovic M, Eggertsen R. Ultrasonic measurement of residual urine is considerate and reliable. *Lakartidningen.* 1999; 96:47-48.

2. Akino H, Wada O, Miwa Y, et al. Ultrasonographic assessment of intravesical urine volume. *Hinyokika Kiyo.* 1990;36:655-660.

3. Memon A, Ather MH. Use of residual fraction instead of residual volume in the evaluation of lower urinary tract symptoms. *Tech Urol.* 2000;6:26-28.

4. Ding YY, Sahadevan S, Pang WS, et al. Clinical utility of a portable ultrasound scanner in the measurement of residual urine volume. *Singapore Med J.* 1996;37:365-368.

5. Lujan Galan M, Paez Borda A, Martin Oses E, et al. Analy-

sis of the reliability of ultrasonic estimates of the posturination residue. *Actas Urol Esp.* 1997;21:117-120.

6. Simforoosh N, Dadkhah F, Hosseini SY, et al. Accuracy of residual urine measurement in men: comparison between real-time ultrasonography and catheterization. *J Urol.* 1997;158:59-61.

7. Nishizawa O, Matsuzaki A, Kohama T, et al. Noninvasive screening procedure for evaluation of bladder-emptying function. *Tohoku J Exp Med.* 1985;147:421-425.

8. Richter S, Hag'ag R, Shalev M, et al. Measuring residual urine by portable ultrasound scanner. *Harefuah.* 1999;137:93-95.

9. Coombes GM, Millard RJ. The accuracy of portable ultrasound scanning in the measurement of residual urine volume. *J Urol.* 1994;152(6 Pt 1):2083-2085.

10. Bent AE, Nahhas DE, McLennan MT. Portable ultrasound determination of urinary residual volume. *Int Urogynecol J Pelvic Floor Dysfunct.* 1997;8:200-202.

11. Brunn J, Ruf G. Ultrasound cystometry for estimating residual urine (author's translation). *Dtsch Med Wochenschr.* 1980 24;105:1501-1503.

12. Beacock CJ, Roberts EE, Rees RW, et al. Ultrasound assessment of residual urine. A quantitative method. *Br J Urol.* 1985;57:410-413.

13. Fuse H, Yokoyama T, Muraishi Y, et al. Measurement of residual urine volume using a portable ultrasound instrument. *Int Urol Nephrol.* 1996;28:633-637.

14. Granados EA, Escobar MR, Alcahe R. The use of transabdominal ultrasound in the estimation of postmicturitional residual urine. *Arch Esp Urol.* 1998;51:473-476.

15. Alnaif B, Drutz HP. The accuracy of portable abdominal ultrasound equipment in measuring postvoid residual volume. *Int Urogynecol J Pelvic Floor Dysfunct.* 1999;10:215-218.

16. McLean GK, Edell SL. Determination of bladder volumes by grayscale ultrasonography. *Radiology.* 1978;128:181-182.

17. Espuela Orgaz R, Zuluaga Gomez A, Torres Ramirez C, et al. Applications of bladder ultrasonography. I. Bladder content and residue. *J Urol.* 1981;125:174-176.

18. Haylen BT, Frazer MI, Sutherst JR, et al. Transvaginal ultrasound in the assessment of bladder volumes in women. Preliminary report. *Br J Urol.* 1989;63:149-151.

19. Haylen BT. Verification of the accuracy and range of transvaginal ultrasound in measuring bladder volumes in women. *Br J Urol.* 1989;64:350-352.

20. Haylen BT, Parys BT, West CR. Transrectal ultrasound to measure bladder volumes in men. *J Urol.* 1990;143:687-689.

21. Pedersen JF, Bartrum RJ, Grytter C. Residual urine determination by ultrasonic scanning. *Am J Roentgenol Radium Ther Nucl Med.* 1975;125:474-478.

22. Poston GJ, Joseph AE, Riddle PR. The accuracy of ultrasound in the measurement of changes in bladder volume. *Br J Urol.* 1983;55:361-363.

23. Kiely EA, Hartnell GG, Gibson RN, et al. Measurement of bladder volume by real-time ultrasound. *Br J Urol.* 1987;60:33-35.

24. Bis KG, Slovis TL. Accuracy of ultrasonic bladder volume measurement in children. *Pediatr Radiol.* 1990;20:457-460.

25. Hiraoka M, Tsukahara H, Tsuchida S, et al. Ultrasonographic evaluation of bladder volume in children. *Pediatr Nephrol.* 1993;7:533-535.

26. Rageth JC, Langer K. Sonographic determination of residual urine. *Urologe A.* 1983;22:87-90.

27. Hakenberg OW, Ryall RL, Langlois SL, et al. The estimation of bladder volume by sonocystography. *J Urol.* 1983;130:249-251.

28. Knorr H, Strauss I, Seichert N. Ultrasound cystometry with reference to urinary bladder form and bladder filling. *Ultraschall Med.* 1990;11:150-154.

29. Paltieli Y, Degani S, Aharoni A, et al. Ultrasound assessment of the bladder volume after anterior colporrhaphy. *Gynecol Obstet Invest.* 1989;28:209-211.

30. Ireton RC, Krieger JN, Cardenas DD, et al. Bladder volume determination using a dedicated, portable ultrasound scanner. *J Urol.* 1990;143:909-911.