

# Outcome of Acalculous Cholecystitis From Typhoid in Nigerian Children

Olajide Lukman Abdur-Rahman, MBBS, FWACS; Olaniyi James Adeniran, FWACS, FICS, FRCS (GLAS), Dip Surg (Paed) (Lond); Adegoke Abdul-Rasheed Nasir, MBBS

**Background:** Gallbladder perforation and gangrene ordinarily follow obstructive (calculous) cholecystitis with a higher frequency among immunocompromised patients or patients with intense inflammation of the gallbladder. The occurrence of typhoid intestinal perforation is common in the tropics, but GBP and gangrene have been reported sparingly. We report management challenges of 6 children with complications of acalculous cholecystitis from typhoid seen at our center.

**Patients and Methods:** The patients were retrospectively sorted from the pediatric surgery unit and theater records of January 2000 to December 2006. Information studied included the patients' biodata, presenting features, operative findings, and outcome of management.

**Results:** There were 6 patients, including 5 boys and a girl, ages ranging 3 to 15 years. The general presentation was that of septicemia. Three had multiple gallbladder perforations, and 3 others had gallbladder gangrene with inflamed Payer's patches on the terminal ileum. All patients underwent open cholecystectomy. There was a case each of postoperative fecal fistula and biliary fistula. All patients survived.

**Conclusion:** Acalculous typhoid gallbladder perforation, though rare, presents with management challenges

**Keywords:** gallbladder ■ children/adolescents

*J Natl Med Assoc.* 2009;101:717-719

**Author Affiliations:** Pediatric Surgery Unit, Department of Surgery (Drs Abdur-Rahman and Adeniran, consultant pediatric surgeons) and Senior Registrar Pediatric Surgery Unit, Department of Surgery (Dr Nasir), University of Ilorin Teaching Hospital, Ilorin, Nigeria.

**Corresponding Author:** Olajide Lukman Abdur-Rahman, MBBS, FWACS, PO Box 5291, Ilorin, 240001, Nigeria (bolarjide@yahoo.com).

## INTRODUCTION

Typhoid fever is a common infection and a cause of intestinal perforation in the tropics with a high morbidity and mortality.<sup>1-4</sup> The occurrence of spontaneous gallbladder perforation (GBP) or gangrene in acalculous cholecystitis is infrequent and very rare following typhoid fever.<sup>5-10</sup> GBP is noted to have high frequency among immunocompromised patients

or patients with intense inflammation of the gallbladder from typhoid fever because *Salmonella* Typhi multiply in the bile in very high titers and are further concentrated in the gallbladder.<sup>11</sup>

The increasing frequency of typhoid ileal perforation and the occurrence of multiple intestinal perforations have been reported from our center.<sup>12,13</sup> Among these cases, those associated with GBP or isolated GBP due to typhoid fever form the basis of this report to emphasize management challenges and suggestions from literature reviews.

## PATIENTS AND METHODS

Six children treated for gangrenous cholecystitis at the University of Ilorin Teaching Hospital, Nigeria, from January 2000 to December 2006 were retrospectively reviewed. Information on their biodata, presentation, mode of treatment, complication, and outcome of management was retrieved from medical records, discharge summaries, and operation notes.

## RESULTS

There were 5 boys and a girl with their ages ranging 3 to 15 years, median 7 years (Table). Mean duration of illness before presentation was 12 days with a range of 7 to 15 days. Out of the 157 children managed for typhoid ileal perforation during the study period,<sup>1</sup> only 2 had associated GBP. Three other patients had isolated gallbladder gangrene with imminent perforation (Figure) and multiple inflamed Payer's patches. One patient had an isolated acalculous typhoid GBP. These 4 patients had positive peritoneal aspirate culture of *S typhi*. All patients presented with typhoid septicemia, though none had jaundice. The 3 patients with gallbladder gangrene had generalized abdominal tenderness and paralytic ileus without rebound tenderness and were thought to have severe typhoid enteritis or possibly a sealed typhoid intestinal perforation because of prolonged use of antibiotics before presentation. Many of these antibiotics were self prescribed and were bought over the counter. All patients were operated on due to deteriorating clinical conditions. Exploratory laparotomy and cholecystectomy were done in all patients, and the 2 patients with

ileal perforation had simple closure of the perforations. One patient had postoperative hemorrhage and hematoma collection in the liver bed that necessitated a reexploration. This patient later developed a fecal fistula that was managed nonoperatively. Another patient had prolonged drainage of bile from drain site in the liver bed, but this spontaneously resolved. The length of hospital admission was between 9 and 43 days (median 14 days). Fecal fistula and biliocutaneous fistula were responsible for the prolonged admissions. All patients are alive and were followed up for 3 to 13 months.

## DISCUSSION

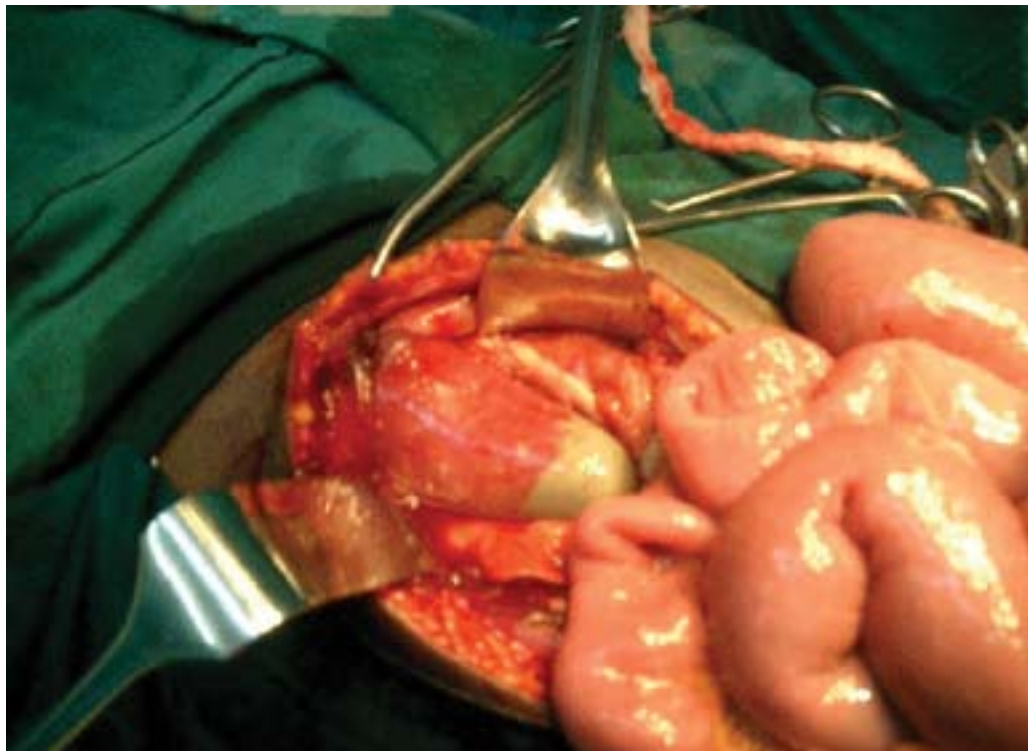
Typhoid GBP is a rare surgical sequel of typhoid infection<sup>6-9</sup> and is hardly suspected preoperatively even in places where typhoid ileal perforation is rampant<sup>1-4</sup> due to common feature of generalized peritonitis. The occurrence of acalculous typhoid GBP has been ascribed to the concomitant presence of intense inflammation, immunosuppression, and highly virulent organisms.<sup>11</sup> This is evident in all these patients and especially 4 of the patients, who had no ileal perforation at surgery. Routine plain radiographs of abdomen and chest for air under diaphragm might have delayed intervention without contributing substantively to diagnosis and treatment.

**Table.** Biodata, Intraoperative Findings, and Complications in Patients With Typhoid Gallbladder Disease

	1	2	3	4	5	6
Patients	AS	GA	FM	KD	RR	AG
Age, y	9	7	3	6	7	15
Sex	Male	Male	Male	Male	Female	Male
Persistent high-grade fever	-	+	+	+	+	+
Generalized abdominal pain	+	+	+	+	+	+
ASA score	IIE	IIIE	IIIE	IIE	IIE	IIE
Gallbladder perforation	+	+	+	-	-	-
Ileal perforation	+	+	-	IPP	IPP	IPP
Length of stay, d	43	9	22	16	12	10
Complications	Hem + fist	Bil - fist	Nil	SSI	SSI	Nil

Abbreviations: +, present; -, absent; ASA: American Society of Anesthesiologists; Bil, biliocutaneous; Fist, fistula; Hem, hematoma; IPP, inflamed payers patches; SSI, surgical site infection.

**Figure.** Gangrenous and Turgid Gallbladder at Laparotomy



Sood<sup>14</sup> suggested high reliability of ultrasound in diagnosing GBP, but at best for 2 patients under review it showed gallbladder distention and presence of sludge. The remaining patients did not have ultrasound scan due presumptively to poor resolution in the face of gaseous bowel dilatation from peritonitis. Shetty and Broome<sup>15</sup> developed a sonographic gallbladder score that assessed the severity of gallbladder changes and predicted the presence of multidrug-resistant strain of *S Typhi* that assisted revision of antibiotics and reduced complications that might have necessitated surgical intervention. This, if used in these patients, might cause further delay in surgical intervention, especially among those with gangrene and imminent perforation, which are unlikely to be reversed by change of antibiotics.

The possibilities of injury to the biliary tree and vascular structures in the face of inflammation have often necessitated the recommendation of a cholecystostomy connected to a tube for drainage. This was not possible in these patients who either had gangrenous gallbladder or multiple perforations located at awkward positions on the gallbladder. We observed that the inflamed tissues at the gallbladder neck could be easily separated with blunt dissection. Hence, a careful and gentle dissection sufficed in the majority of the patients managed.

The fecal fistula in a patient with unidentified liver bed bleed was an unexpected morbidity that may be from injured/trapped bowel during reexploration. The prolonged biliary leak in another patient through the drain site might have resulted from unidentified aberrant bile duct from the liver bed.

Many series have reported high mortality among patients with acute GBP.<sup>16</sup> In spite of the grave morbidity recorded in the 2 patients, all our patients survived due to appropriate interventional and supportive care.

The diagnosis of acute cholecystitis in children requires

high index of suspicion to prevent the potentially life-threatening complications of perforation and gangrene. Though management is very challenging, the outcome is good with early intervention and cholecystectomy.

## REFERENCES

1. Adeniran JO, Taiwo JO. Typhoid Intestinal Perforation in Children: Salmonella Versus The Surgeon: Who Is Winning The Race? *Trop J Health Sci*. 2008;15:61-65.
2. Uba AF, Chirdan BL, Ituen AM, et al. Typhoid Intestinal perforation in Children: a continuing scourge in developing country. *Pediatr Surg Int* 2007;23:33-39.
3. Irabor DO. Fifteen years of typhoid perforation in children in Ibadan: still a milestone around the surgeon's neck. *Niger J Surg Research*. 2003;5:92-99.
4. Ugwu BT, Yiltok SJ, Kidmas AT, et al. Typhoid intestinal perforation in north central Nigeria. *West Afr J Med*. 2005;24:1-6.
5. Shukla VK, Khaudelwal C, Kumar M, et al. Enteric Perforation of the gallbladder. *Postgrad Med J*. 1983;59:125-126.
6. Memon AA. Perforated gall bladder: A case report. *J Surg Pak* 2001;6:37-38.
7. Kamble AT, Sarda DK, Chaudhary N, et al. Gallbladder Perforation in typhoid fever. *J Indian Assoc Pediatr Surg*. 2003;8:249-250.
8. Saxena V, Basu S, Sharma CLN. Perforation of the gall bladder following typhoid fever-induced ileal perforation. *Hong Kong Med J*. 2007;13:475-477.
9. Chirdan LB, Iya D, Ramyil VM, et al. Acalculous cholecystitis in Nigerian children. *Pediatr Surg Int* 2003;19:65-67.
10. Ameh EA. Cholecystitis in Children in Zaria, Nigeria. *Ann Trop Pediatr* 1999;19:205-209.
11. Christie AB. Typhoid and paratyphoid fever. In Christie AB, ed. *Infectious Disease- Epidemiology and Clinical Practice*. 3rd ed. New York, NY: Churchill Livingstone; 1980:47.
12. Nasir AA, Adeniran JO, Abdur-Rahman LO, et al. Typhoid Intestinal Disease: 32 perforations in 1 patient. *Niger Postgrad Med J*. 2008;15:55-57.
13. Adeniran JO, Taiwo JO, Abdur-Rahman LO. Salmonella intestinal perforation: (27 perforation in one patient, 14 perforations in another) Are the goal post changing? *J Indian Ass Pediatr Surg*. 2005;10:248-251.
14. Sood BP, Kalra N, Gupta S, et al. Role of sonography in the diagnosis of gallbladder perforation. *J Clin Ultrasound*. 2002;30:270-274.
15. Shetty PB, Broome DR. Sonographic Analysis of Gallbladder Findings in Salmonella Enteric Fever. *J Ultrasound Med*. 1998;17:231-237.
16. Essenhigh DM. Perforation of the gallbladder *Br J Surg*. 1968;55:175-178. ■